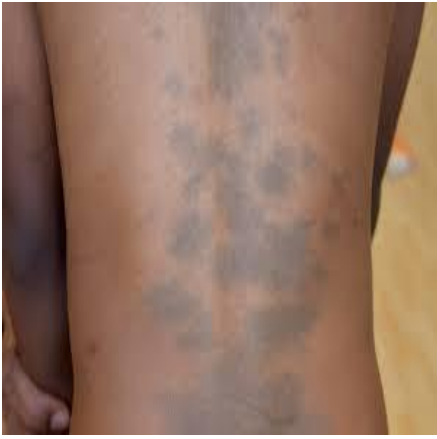

## **DX: Mongolian Spots    RX:**



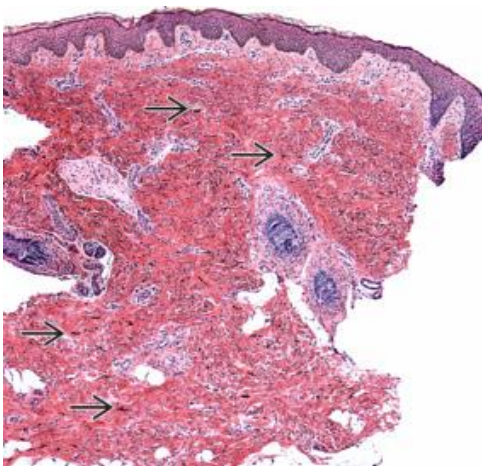
**1. Parents helps to reassure them.**

### **C/C:**

Flat & Smooth Marks  
(Spot) Like Bruises on  
the Lower back,  
Buttocks & Upper legs.  
(Brown, grey, blue macules)

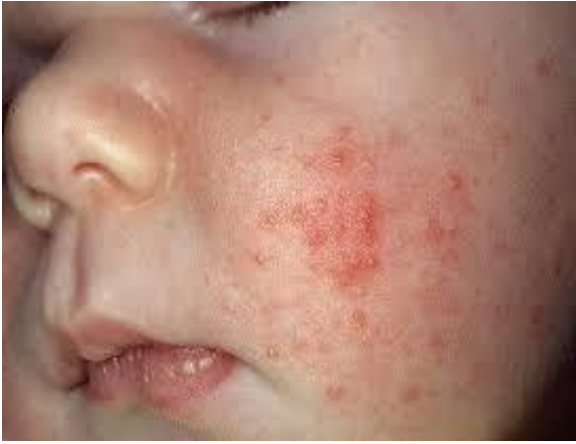### **Investigations:**

#### **Dermatopathology**



This low-magnification view of a Mongolian spot shows a normal epidermis and pigmented cells

## **DX: Neonatal Acne**



## **RX:**

- 1. Require no treatment.**
- 2. The lesions tend to subside by 2-3 weeks.**

## **C/C:**

**Little Bumps & pustules on the infant's forehead, cheeks, eyelids, & chin area.**

## **Investigations:**

**Dermatopathology**

